



Case study

A case report of hepatic perivascular epithelioid cell tumours (pecomas) and literature review

Nguyen Duc Duy^a, Nguyen Phan Xuan Truong^a, Phan Dang Anh Thu^a, Ngo Quoc Dat^a

^aDepartment of Pathology, University of Medicine and Pharmacy at Ho Chi Minh City

Received March 26, 2018; Accepted July 01, 2018; Published online July 08, 2018

Abstract: Perivascular epithelioid cell tumours (PEComas) belongs to the family of mesenchymal neoplasms that can occur in many organs, but rarely found in liver. Preoperative diagnosis could be challenging due to unspecific and variable radiologic patterns, which can be clinically misdiagnosed with hepatocellular carcinoma and other benign tumors. This report aims to announce a case of hepatic PEComa with extramedullary hematopoiesis. A 44-year-old woman accidentally presented a nodular mass in the left hepatic segment on ultrasonography with normal liver function result. Abdominal enhanced CT Scan showed hypervascular lesion. Morphology exhibits classical characteristics of PEComa with mature fat tissue predominance, thick-wall vessel; somewhat amount of extramedullary hematopoiesis was also recognized. Tumor cells are diffusely immunoreactive with HMB45. PEComa is a rare disease in liver, pathologists need to recognize three components of this tumor to avoid misdiagnosing with malignant conditions.

Keywords: Perivascular epithelioid cell tumours (PEComas), Hepatocellular Carcinoma (HCC), HMB45, extramedullary hematopoiesis.

1. INTRODUCTION

In 2002, PEComas were defined as “mesenchymal tumors composed of histologically and immunohistochemically distinctive perivascular epithelioid cells” by The World Health Organization (WHO) [10]. Later in 2013, this family of neoplasm was defined by WHO as mesenchymal tumors that usually express melanocytic and smooth-muscle markers. PEComas family includes angiomyolipoma (AML), clear cell sugar tumor of lung (CCST), lymphangioliomyomatosis (LAM)... [1]. PEComas can arise in many organs; and uterus is the most common site. Hepatic PEComas are extremely rare [3]. Moreover, it is very difficult to draw correct diagnosis of PEComas clinically because it is often misdiagnosed with other tumors [2]. We report here a case of primary hepatic PEComa occurring in 44-year-old woman with literature reviews.

2. CASE REPORT

History

In February 3th, 2017, a 44 years old woman came to University Medical Center for Health check up and performed abdominal ultrasonography. She was accidentally detected a liver tumor. Laboratory test revealed a normal liver function. CT Scan highlighted a hypervascular lesion in left liver which can not exclude hemangioma, adenoma, AML... (Figure 1).

Pathology report

Gross appearance:

Tumor was measured 6x4 cm in dimensions, relatively well-demarcated, not encapsulated with red cut surface (Figure 2).

*Address correspondence to Nguyen Duc Duy, Department of Pathology, University of Medicine and Pharmacy Ho Chi Minh City, 217 Hong Bang Street, District 5, Ho Chi Minh City, Vietnam.
Email: duynguyen041192@outlook.com.vn, Tel: +84904974422
DOI: 10.32895/UMP.MPR.2.2.39

Microscopic findings:

The tumor mainly composed of epithelioid cells, which had abundant granular eosinophilic cytoplasm, eccentrically located round nuclei with small nucleoli, and foci of mild to moderate nuclear atypism. Mitotic figure or necrosis was not observed. The nest or trabecular patterns of tumor cells were surrounded by thin-walled capillary vessels

as well as thick and hyalinized blood vessels. Adipose tissue is also predominant. Scatter foci of extramedullary hematopoiesis was recognized. Foam cells and melanin-like brown pigments sparsely appeared in the sinusoidal spaces between the tumor cells. The tumor cells are strongly and diffusely immunoreactive for melanotic marker (HMB45) and negative with Desmin (Figure 2).

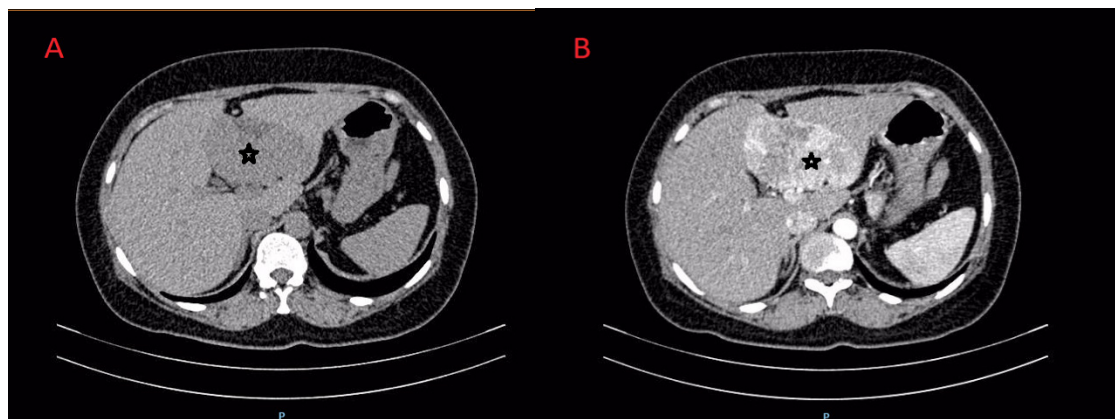


Figure 1: Enhanced abdominal ct scan. Low-density lesion at plain phase, higher density one at arterial phase. A: CT Scan, plain phase, B: CT Scan, arterial phase, *: tumor

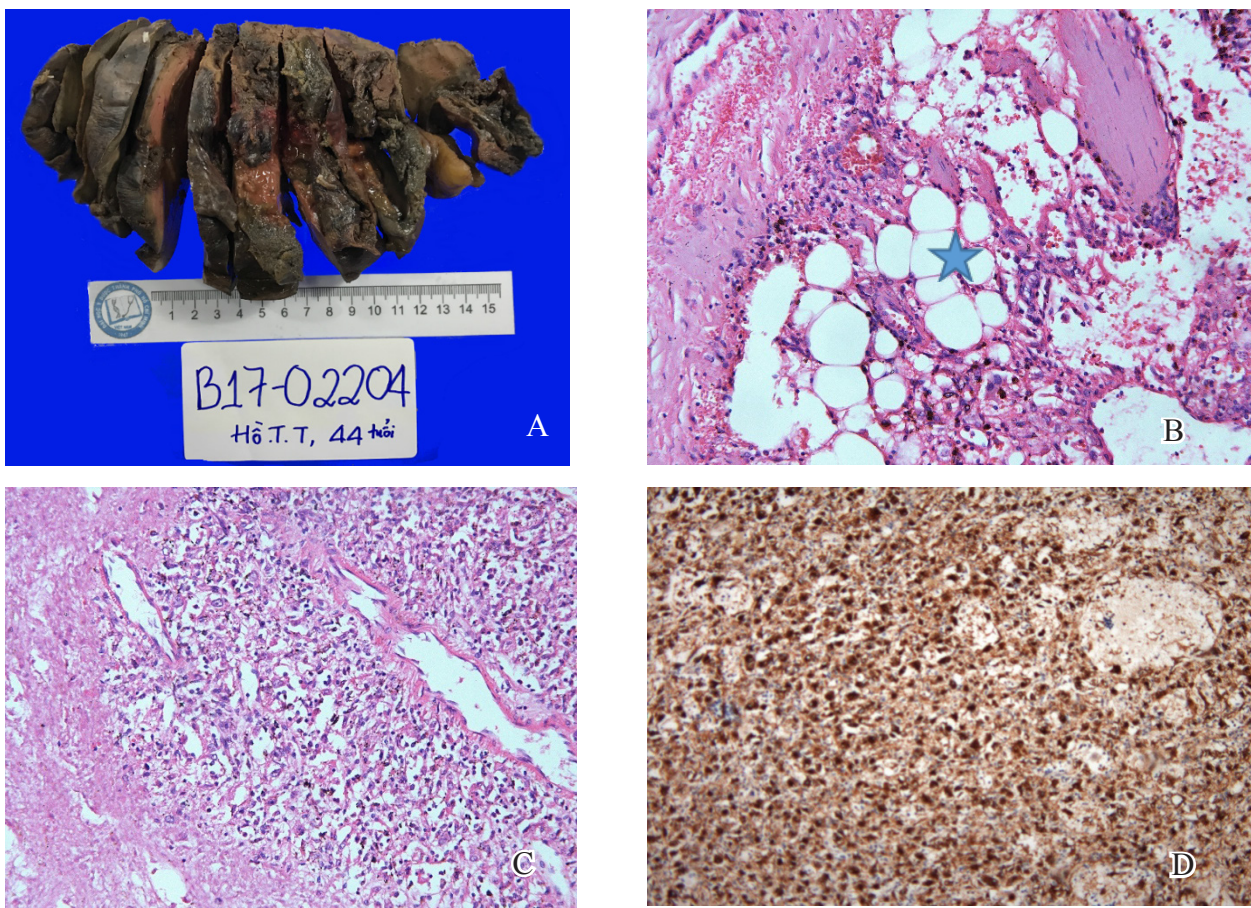


Figure 2: (A) Gross findings of hepatic PEComa; (B) Mature adipose tissue appears on hypervascular background, B17-2204, HE x200 (*); (C) Thick and hyalinized blood vessel; (D) Diffuse immunochemical reaction with HMB45

3. DISCUSSION

PEComa is a novel terminology for mesenchymal tumor with feature of perivascular epithelioid cell which was defined by WHO in 2002. The most common primary sites of PEComa at presentation are the uterus, vulva, rectum, heart, breast, urinary bladder... [1]. Although PEComas are commonly asymptomatic, they may present with vague pain. Hepatic PEComa is rather rare with clinical characteristics similar to other hepatic primary tumor; therefore, it is often misdiagnosed with other tumors [2]. The enhanced and drainage imaging patterns of hepatic PEComas are mimic those of hepatocellular carcinoma (HCC). Contrast enhanced ultrasonography showed early influx of the contrast agent into the tumor and rapid drainage of arterial blood to veins. In addition, power Doppler ultrasonography, which revealed displaced vessels around the tumor [2]. On CT scan, most neoplasms present as hypo intense with significant enhancement on arterial phase. The portal phase was variable. Almost all lesions reported show low-signal on T1-weighted images, high-signal on T2-weighted images [4]. Hepatic PEComa should be distinguished from focal nodular hyperplasia (FNH), hemangioma, adenoma, and other hepatic tumors [5].

In our case, hepatic tumor appeared hypervascular with low enhancement during venous phase, which is so challenging in differential diagnosis with HCC. The portal phase was variable. Almost all lesions reported show low-signal on T1-weighted images, high-signal on T2-weighted images. These radiologic findings can be confused, most often, with those of hepatocellular carcinoma or simple haemangioma [4]. In a study of Tan Y et al., 3/7 cases were diagnosed HCC preoperatively, 2/7 cases were diagnosed FNH preoperatively and 2 cases without preoperative diagnosis [2]. Diagnosis of PEComa on CT Scan can rely on fat tissue, but of 12 cases reported by Tay S et al., 5 cases revealed a well-demarcated mass without fatty density on CT scans [5]. Liver adenoma and HCC also have fat compartment. Owing to that, morphology plays an important role in making a correct diagnosis of PEComa.

Grossly, tumor is usually found single, with median size about 8 cm in diameter, well-demarcated, without a capsule. Cut surface appear yellow or brown depending on the component of fat tissue. Necrosis and hemorrhage may be found in large tumor [1]. Tumor cells appear epithelioid, which have abundant granular eosinophilic cytoplasm, distinct cell border, eccentrically located round nuclei with small nucleoli. Tumor cells are arranged in dense sheets as epithelial-like pattern with abundant dilated vascularity [1]. These tumors are positive for HMB45, Melan-A, S-100, and SMA, but negative for CgA, Syn, CK, CD117, CD10, and CD34 [1]. In our case, the tumor cells are negative for Desmin. Folpe AL et al. showed that only 8/22 cases of PEComa positive with Desmin, while HMB-45 was the most specific marker for PEComa disease [8]. To archive final

diagnosis, the pathologists need to mention the present of adipose tissue, as well as thick-walled arterial or thin-walled venous-like spaces for not confusing with other primary liver mesenchyme tumors or GIST and melanoma liver metastasis.

The histopathologic differential diagnoses of PEComa are quite numerous and influenced by the tumor sites and morphology. Our present case was consistent with monomorphic variants of PEComas, composed almost exclusively of epithelioid cells and with blood vessels and adipose tissues. For confirmation, immunohistochemical stains for HMB45 or Melan A should be performed. Moreover, in our case, foci of extramedullary hematopoiesis were also observed. In our case, the tumor cells were diffusely and strongly immunoreactive for HMB45 but not for Desmin. Metastatic clear cell carcinoma from kidney or adrenal glands could be excluded from the absence of the tumor in the primary sites.

The origin of tumor is still a dispute. As hypothesis, the tumor comes from neural crest, another tells that the origin is perivascular smooth muscle or myoblast [7]. PEComas can display characteristics of both benign and malignant tumors and the primary treatment is resection. PEComas displaying any combination of infiltrative growth, marked hypercellularity, high nuclear grade and hyperchromasia, high mitotic activity (> 1 mitotic figure / 50 HPF), atypical mitotic figures, and coagulative necrosis should be regarded as malignant [8]. Tumor size > 5 - 8 cm is also one of poor prognostic factors of PEComa [8]. According to Folpe AL et al, recurrence and/or metastasis of PEComa was strongly related to tumor size, mitotic activity, and necrosis [8].

4. CONCLUSION

PEComa is reported in many organs, but rarely in liver. Preoperative diagnosis of hepatic PEComa is challenging, so that the role of pathology is very important to draw final diagnosis. PEComa has exclusive morphology and coexpression with muscle and melanocytic markers. PEComa is not always benign; Small PEComas without any worrisome morphological features are most likely benign.

REFERENCES

1. Khaja F, Carilli A, Baidas S, Sriharan A, Norford S. PEComa: A Perivascular Epithelioid Cell Tumor in the Liver—A Case Report and Review of the Literature. *Case Reports in Medicine*. doi:10.1155/2013/904126. 2013:1-4.
2. Tan Y, Xiao E-H. Hepatic perivascular epithelioid cell tumor (PEComa): dynamic CT, MRI, ultrasonography, and pathologic features—analysis of 7 cases and review of the literature. *Abdominal Radiology*. doi:10.1007/s00261-012-9850-1. 2012;37(5):781-7.
3. Fang S-H, Zhou L-N, Jin M, Hu J-B. Perivascular epithelioid cell tumor of the liver: A report of two cases and review of the literature. *World Journal of Gastroenterology: WJG*. doi:10.3748/wjg.v13.i41.5537. 2007;13(41):5537-9.

4. Ameurtesse H, Chbani L, Bennani A, et al. Primary perivascular epithelioid cell tumor of the liver: new case report and literature review. *Diagnostic Pathology*. doi:10.1186/1746-1596-9-149. 2014;9(1):149.
5. Shen HQ, Chen DF, Sun XH, et al. MRI diagnosis of perivascular epithelioid cell tumor (PEComa) of the liver. *Rom J Morphol Embryol*. 2013;54(3):643-7.
6. Tay S, Lao W, Chen C, Chan W. Contrast-enhanced ct and angiographic findings in hepatic perivascular epithelioid cell tumor. *Journal of the Belgian Society of Radiology*. doi:10.5334/jbr-btr.428. 2013;96(5):308.
7. Son H-J, Kang DW, Kim JH, Han HY, Lee MK. Hepatic perivascular epithelioid cell tumor (PEComa): a case report with a review of literatures. *Clinical and Molecular Hepatology*. doi:10.3350/cmh.2016.0034. 2017;23(1):80-6.
8. Folpe AL, Mentzel T, Lehr H-A, Fisher C, Balzer BL, Weiss SW. Perivascular Epithelioid Cell Neoplasms of Soft Tissue and Gynecologic Origin. *The American Journal of Surgical Pathology*. doi:10.1097/01.pas.0000173232.22117.37. 2005;29(12):1558-75.
9. Bonetti F, Pen M, Martignoni G, et al. The Perivascular Epithelioid Cell and Related Lesions. *Advances in Anatomic Pathology*. doi:10.1097/00125480-199711000-00001. 1997;4(6):343-58.
10. Fletcher CDM, Unni KK, Mertens F. World Health Organization classification of tumours. In: Mertens F, ed. *Pathology and genetics of soft tissue and bone*. Lyon: IARC Press. 2002:221-2.